

Evaluation and Treatment of Musculoskeletal Vascular Anomalies in Children: An Update and Summary for Orthopaedic Surgeons

J.A. McCARRON,¹ D.R. JOHNSTON,¹ B.G. HANNA, M.D.,¹ D.W. LOW, M.D.,² J.S. MEYER, M.D.,³ M. SUCHI, M.D., PH.D.,⁴
AND J.P. DORMANS, M.D.¹

Abstract: The majority of vascular anomalies can be categorized as either hemangiomas or vascular malformations. Hemangiomas are the most common benign soft tissue tumors of childhood, occurring in 4%–10% of children [16]. Vascular malformations represent a separate group of congenital vascular anomalies. Both hemangiomas and vascular malformations are often located deep to the deep fascia in the trunk and extremities of children and can present with signs and symptoms similar to that of malignant soft tissue tumors such as rhabdomyosarcomas. Given the high prevalence of vascular anomalies in the pediatric population, and the need to distinguish them quickly and accurately from other soft tissue tumors, any orthopaedic surgeon treating children must have a solid understanding of the presentation, diagnosis, and prognosis of hemangiomas and vascular malformations. Confusion still exists in the literature and among clinicians about classification and treatment of these vascular anomalies. The biological classification system proposed by Mulliken and Glowacki [17] offers a simple and effective means of evaluating and diagnosing children with vascular anomalies and aids in the formulation of appropriate treatment plans.

Introduction

Vascular anomalies may be the result of neoplastic endothelial hyperplasia or the result of a congenital malformation. These lesions often occur on the extremities or trunk, where they may present as an enlarging soft tissue mass in the subcutaneous tissues, or may be located deep to the deep fascia, and involve the musculoskeletal system. Despite the relatively benign nature of vascular anomalies, the differential diagnosis at first presentation may include soft tissue tumors and sarcomas that occur in the pediatric population. Due to the high prevalence of vascular anomalies in children, orthopaedic surgeons must have a firm comprehension of vascular malformations and hemangiomas so that they can distinguish them from other soft tissue tumors, and initiate a proper treatment plan.

From the ¹Division of Pediatric Orthopaedic Surgery, The Children's Hospital of Philadelphia, ²Division of Plastic Surgery, The Children's Hospital of Philadelphia, ³Department of Radiology, The Children's Hospital of Philadelphia, and ⁴Department of Pathology, The Children's Hospital of Philadelphia, Philadelphia, PA.

Address correspondence to: John P. Dormans, M.D., Chief of Orthopaedic Surgery, Children's Hospital of Philadelphia, 2nd Floor Wood Bldg., 34th and Civic Center Blvd., Philadelphia, PA 19104-4399.

Accurate nomenclature for vascular anomalies is central to understanding the etiology of these lesions and to developing an appropriate treatment plan [7,14–16,18], however, much of the current terminology used to categorize vascular anomalies is inconsistent. The biological classification system, which was developed by Mulliken and Glowacki in 1982, offers a clear, effective method of describing these lesions [17]. Children with hemangiomas, are usually referred to a plastic surgeon for observation or treatment is usually the best option. Children with vascular malformations of the trunk or extremities may require more definitive surgical procedures requiring the skills of a team, including an orthopaedic surgeon that is familiar with these lesions.

Nomenclature

In 1982 Mulliken and Glowacki proposed the biological classification system [17]. This system divides vascular anomalies into hemangiomas, which are neoplastic lesions with endothelial hyperplasia, and vascular malformations, which are congenital lesions with normal endothelial turnover [18]. Vascular malformations can then be further subclassified by the predominant type of vessels found within the lesion (i.e., venous, arterial, lymphatic, capillary, or mixed) and upon blood flow within the lesion (i.e., high flow vs. low flow) (Table 1). It should be noted, however, that histologic and radiologic subclassification can be difficult because of overlapping characteristics (Fig. 1).

The biological classification system has proven very useful clinically in establishing a clear diagnosis and prognosis for vascular lesions, and has been shown to correlate well with angiographic [15], ultrasound, and magnetic resonance imaging (MRI) findings [5,7]. The increasingly wide-spread use of the biological classification system not only simplifies the diagnosis of these lesions, but facilitates precise communication between physicians, which is necessary for a multiple-subspecialty team approach to patient treatment (Table 2) [6,7].

Vascular Malformations

Etiology

During vasculogenesis, mesodermal cells initially located in the embryonic yolk sac migrate throughout the fetus and

Table 1. Biological classification system of vascular anomalies

Etiology	Blood flow	Vessel type
Vascular malformations	Slow flow	venous malformation lymphatic malformation capillary malformation mixed-type malformation veno-lymphatic capillary-veno-lymphatic
	Fast flow	arterio-venous malformation mixed-type malformation arterio-veno-lymphatic capillary-arterio-veno-lymphatic
Hemangioma	Slow/fast flow	Infantile hemangioma Kaposiform hemangioendothelioma Hemangiopericytoma Epithelioid hemangioendothelioma Endovascular papillary angioendothelioma Angiosarcoma

Data from references [16] and [18].

organize to form primitive blood vessels that will eventually give rise to a mature vascular system [22]. Molecular research supports theories that the lymphatic system then develops by a process of budding off the primitive venous vessels (centrifugal theory) [16].

At birth, vascular malformations are fully formed (although the lesion may not be clinically apparent) and their cells possess no propensity for independent neoplastic transformation or proliferation [22]. Vessel dilatation or hematoma formation may cause rapid enlargement or the appearance of a previously undocumented vascular malformation. It is important to recognize, however, that although swelling and dilation may occur, vascular malformations grow in

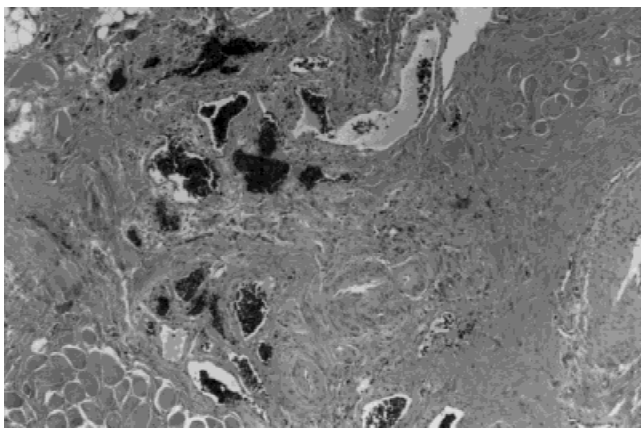


Fig. 1. Vascular malformation of skeletal muscle and fibrous tissue is dissected by abnormal and disorganized vascular structures. The vessels are heterogeneous, with some having thick muscular walls, some having a capillary or cavernous appearance, and many being intermediate in appearance. ($\times 100$)

proportion to the patient. Unlike hemangiomas, they do not extend their boundaries or further invade adjacent structures, nor will they involute or regress over time [14].

Males and females are equally affected by vascular malformations, which are usually sporadic. However, germ-line or somatic mutations, and genetic disorders such as Sturge-Weber syndrome may also be associated with these lesions.

Venous malformations (VM)

Epidemiology

Twenty percent of venous malformations are located on the trunk, 40% on the extremities, and 40% on the head and neck [7]. The majority of these lesions involve the skin and subcutaneous tissues, but extensive involvement of structures such as muscle, joint, bone, abdominal viscera, and CNS structures is not uncommon [16].

Natural history

Venous malformations do not possess the potential for independent growth, but over time, progressive vascular dilation usually occurs [7,14,16,18]. Many venous malformations remain asymptomatic. However, complications arising from these lesions include pain secondary to vessel dilation, bleeding, and hematoma formation, in addition to intra-articular involvement, hemarthrosis, and pathologic fractures of bone [7]. Venous malformations can also lead to skeletal and soft tissue under or over-growth in an affected limb [16]. Thrombosis and thrombophlebitis may also occur, and clotting studies can indicate a chronic, low-grade disseminated intravascular coagulation [7].

Diagnosis

Diagnosis of a venous malformation can often be made based on physical exam findings and history of growth proportional to that of the patient [14,16,18]. Superficial venous malformations present as a soft, compressible, non-pulsatile mass with a bluish discoloration. However, these findings are less apparent and may be limited to an unremarkable soft tissue mass or symptoms of pain when the lesion is intramuscular or located deep to the deep fascial layer. Plain X-ray films are of limited use except in identifying phleboliths, which are pathognomonic for this type of malformation [8]. Doppler ultrasound can be used to confirm that a lesion is low-flow in nature, thereby ruling out the arterial involvement that is characteristic of arteriovenous malformations [7]. MRI is an excellent imaging modality for confirming the nature of the lesion and defining its relationship to adjacent structures (Table 2) (Fig. 2) [7,16].

Histologically, venous malformations are characterized by dilated, thin walled, channels with flattened, normochromic endothelial cells surrounded by smooth muscle fibers arranged in abnormal clumps [16]. Pathognomonic phleboliths may be seen [16], and because of the propensity for thrombophlebitis, the normally thin-walled vessels may display adventitial fibrosis and inflammatory cells [6].

Treatment

Compression stockings to prevent progressive venous dilation, pain, ulceration, and bleeding are the mainstay of

Table 2. Clinical characteristics and diagnostic features of vascular anomalies

Anomaly type	Natural history/clinical presentation	Histologic features	MRI features
Venous malformation	grows proportionately with child may present with thrombosis, thrombophlebitis, or low-grade disseminated intravascular coagulation	dilated, thin-walled channels with smooth muscle fibers in clumps flattened endothelial cells	T1—low intensity T2—high intensity may have variable intensity due to hemorrhage or thrombosis slow flow lesions
Arteriovenous malformation	noticeable at birth because of cutaneous blushing and localized warmth 4 stages (some never pass first stage: Quiescence, Expansion, Destruction, Decompensation)	heterogeneous lesion with large vessels intimal thickening of veins tortuosity of vessels increased fibrin deposition (stage 3)	T1—low intensity T2—low intensity flow voids caused by rapid, turbulent blood flow
Lymphatic malformation	mild to massive lymphedema OR multicystic masses with viral/bacterial infection localized multicystic lesions will present with vesicle rupture, weeping of lymphatic fluid frequently seen with capillary, venous, or AV malformation most commonly hypoplastic, but can be hyperplastic, or multicystic	hypoplastic: hypoplastic lymphatic channels and small fibrotic lymph nodes hyperplastic: enlarged lymphatic channels lacking valves, small and sparse lymph nodes multicystic: numerous lymphatic sacs with normal lymph channels	T1—low intensity (occasionally variable) T2—high intensity (occasionally variable) Slow flow lesion Septa may enhance following gadolinium
Capillary malformation	noticeable at birth grows proportionately with child with some dilation and darkening with age macular at birth and raised in adulthood intermittent break-down and bleeding may be mixed type containing venous, AV, or lymphatic components	Dilated capillary network of variable density, located in the dermis Paucity of intradermal nerve fibers in area of capillary dilation	Not applicable
Mixed-type malformation	can have overlapping characteristics depending upon composition	can have overlapping characteristics depending upon composition	Variable. Consistent with findings of individual components
Hemangioma	rarely involve bone/muscle hypertrophy majority noticeable during first month of life initially presents as cutaneous blanching, telangiectasia, or small red pupule 3 phases: Proliferative (1–8 mo of age), Involution (8 mo–2 yr of age), Involved	plump, rapidly-dividing endothelial cells increased number of mast cells multilaminated basement membrane	T1—intermediate intensity T2—high intensity Lobulated soft tissue mass with well defined borders Flow voids may be present Equitorally located feeding the draining vessels

Data from references [14], [16], [7], [18], and [6].

treatment, and low dose aspirin may also be used to minimize thrombophlebitis [14]. For those patients who do not receive adequate benefit from compression stockings, laser surgery, sclerotherapy, and/or surgical resection are all widely accepted treatment methods [14,16]. Sclerotherapy

with 100% ethanol, surgical resection, or often a combination of the two may be used to achieve palliation or to decrease symptoms in the case of selected deeper venous malformations [16]. Epiphysiodesis may be required for patients with extensive venous malformations that have re-

sulted in skeletal overgrowth. Additionally, surgical intervention by an orthopedists may need to treat deep venous malformations involving muscle or bone, which have led to pain, functional impairment or pathologic fracture. In superficial venous malformations, laser therapy with Neodymium: Yttrium Aluminum Garnet (Nd:YAG) laser can be used to cause non-specific deep coagulation [14].

Arteriovenous malformations

Epidemiology

Most commonly, arteriovenous malformations (AVMs) involve the head and neck, followed by the lower extremities and trunk [8]. The lesions may be located superficially with only minimal arterio-venous shunting or more deeply with significant, high flow, AV shunting. As is true for all

vascular malformations, the incidence of AVMs between males and females is equal.

Natural history

AVMs are usually noticeable at birth because even the deeper lesions cause cutaneous blushing and localized warmth. The natural history for these lesions follows four stages described by Schobinger as quiescence, expansion, destruction, and decompensation (Table 3) [13,16]. Progression through these stages may be partial or complete. Like VMs, AVMs may also cause skeletal overgrowth.

Diagnosis

Clinical exam and patient history are usually adequate for accurate diagnosis of these lesions. The initial cutaneous blushing may mislead the clinician to diagnose a capillary hemangioma, however, the absence of a rapid growth phase

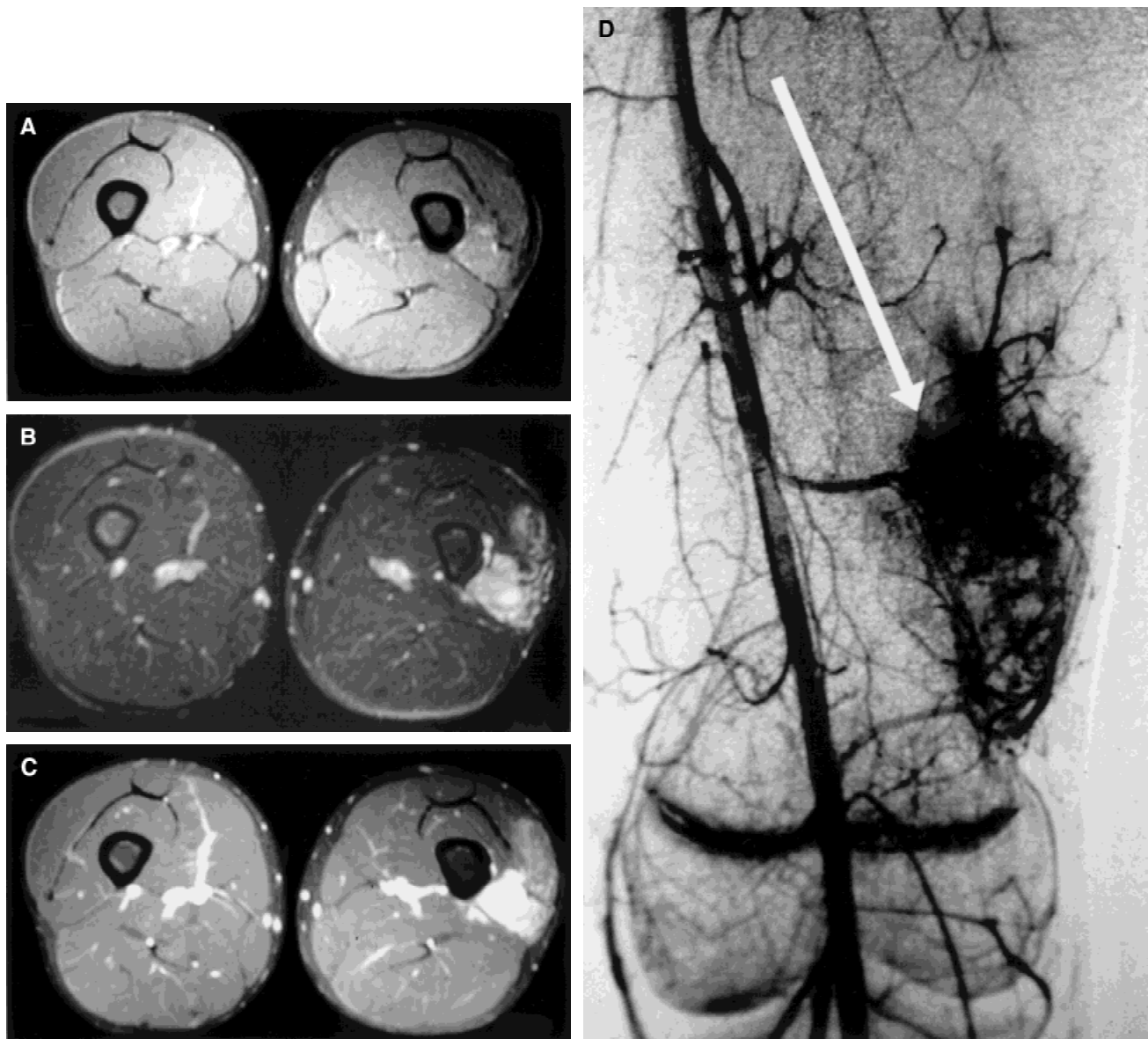


Fig. 2. A15-year-old boy with venous malformation of left thigh. (A) Axial T1 weighted fat saturated image shows subtle signal abnormality in left vastus lateralis muscle. (B) Axial fast spin echo T2 weighted fat saturated image shows obvious high signal abnormality in same region. (C) Axial T1 weighted fat saturated image obtained after intravenous injection of gadolinium-DTPA shows dense enhancement of lesion. (D) Venous phase of arteriogram shows pooling of contrast and confirms vascular nature of lesion.

during the first month of life suggests that the lesion is a vascular malformation since true hemangiomas display a proliferative phase during the first weeks after birth. Physical exam is usually adequate to separate arteriovenous malformations from venous malformations as the presence of a thrill, bruit, or pulsation indicates the presence of an arterial component to the lesion [16]. Larger AVMs causing an increased cardiac output may demonstrate reflex bradycardia after compression of the lesion (Branham's Sign) which is another finding that is not associated with a purely venous malformation [8]. Ultrasound or color doppler is effective in evaluating these malformations, which appear as heterogeneous lesions with large vessels and multiple sites of pulsatile AV shunting [7]. MRI/MRA is an excellent modality for evaluating the local extent of arteriovenous malformations and for separating them from venous malformations based on the MRI differences listed in Table 2. Nevertheless, angiography is still helpful for those patients requiring surgical interventions or preoperative embolization (e.g., resection of intramuscular lesions) [7,14,16].

Insults such as trauma have been known trigger expansion of previously quiescent AVMs, so biopsy should be performed only if necessary. Histology results from surgical specimens will demonstrate thickening of the venous intima (arterialization) and tortuosity of the vessels. In AVMs that have progressed to stage three (destructive), increased perivascular fibrin deposition is often present secondary vascular engorgement and chronic venous stasis.

Treatment

AVMs can prove deceptively problematic and even dangerous to treat. Thus, most authors agree that conservative

treatment is preferred in the absence of significant symptoms [14,16]. Deep AVMs that have progressed to the destructive phase may cause significant muscle or bone changes and will necessitate surgical debulking or epiphysiodesis by an orthopaedic surgeon. When surgery is required, angiographic studies followed by selective embolization is usually done 24 to 72 hours before resection [16]. It should be emphasized that embolization or ligation of feeding arteries without surgical resection is strongly contraindicated because occlusion of the major feeding arteries usually results in rapid recruitment and dilation of previously microscopic collateral blood flow [14,18]. Superselective embolization followed by sclerotherapy represents a non-surgical option; however, the risk of complications with this procedure is high [16].

Lymphatic malformations

Etiology/Epidemiology

Lymphatic malformations (LMs) may occur as a solitary lesion but often they are seen in association with capillary, venous, or arteriovenous malformations and are also associated with a number of genetic syndromes including Turner Syndrome, Trisomy 13, 18, and 21 [16].

The incidence of LMs is similar in males and females. The head and neck are the most common anatomic locations, followed by the axilla and lower extremities. Many lesions are noticed at birth and the majority present before age two. It is possible, however, for these lesions to first present later in life [4,16].

Natural history

Patients may have lymphedema (usually mild), or massive edema with associated skeletal and soft tissue overgrowth. Conversely, multiple cystic masses that may rapidly increase in size, usually due to viral or bacterial illness or intra-lesional hemorrhage, may be seen with or without lymphedema. Vesicle rupture, with weeping of lymphatic fluid and subsequent cellulitis is common for cutaneous lesions. Although the majority of LMs persist throughout the patient's lifetime, complete or partial spontaneous regression during the first two decades of life has been documented [4].

Histologically, LMs may present as hypoplastic or atretic lymphatic channels with small fibrotic lymph nodes, or as enlarged lymphatic channels lacking valves. Localized multicystic LMs consist of numerous subcutaneous lymphatic sacks that do not connect with the normal lymphatic channels, forcing accumulated lymph fluid to erupt onto the skin as vesicles.

Diagnosis

Diagnosis is based on clinical findings of extremity edema, cutaneous lymph-filled vesicles or subcutaneous cystic mass(es). When imaging of the lesions is desired, MRI best defines the nature of the lesion and its local extent (Table 2) [16]. Ultrasound is also appropriate for evaluating

Table 3. Schobinger's natural history of arterio-venous malformations

Stage of natural history	Characteristic findings
Quiescence	Cutaneous blush and increased warmth of skin (Many AVMs never progress past the Quiescent stage)
Expansion	Darkening cutaneous blush, enlarging soft tissue mass and increased cardiac output s AV fistula enlarges (Expansion starts in childhood or early adolescence often in response to puberty or trauma)
Destruction	Arterial steal worsens, causing distal ischemia, pain, and necrosis Increased total blood flow causes edema, dystrophic skin changes, ulceration, bleeding Soft tissue and bone hypertrophy may occur
Decompensation	High output cardiac failure (Only the largest AVMs reach this stage)

Data from reference [13].

lymphatic malformations when the cystic component is larger [7].

Treatment

Compression garments are the mainstay of treatment and can be used to diminish the accompanying chronic lymphedema, skin breakdown, and skeletal and soft tissue overgrowth. When compression garments fail, surgical debulking procedures or epiphysiodesis may be required. Due to the diffuse nature of these lesions, surgery is most often aimed at palliative debulking of soft tissues, and at epiphysiodesis, when indicated, as opposed to an attempted cure. Sclerotherapy with 100% ethanol can also be used to treat cystic lymphatic malformations.

For patients with localized multicystic LMs, surgery or laser therapy are the usual treatment options, although, both are associated with significant recurrence rates. For superficial lesions surgery often involves resection down to the deep fascia and subsequent split thickness skin grafting [16]. Deep lesions, if accessible, can be surgically treated with marginal resection and, if they involve multiple tissue planes or types, stepwise debulking is preferred [16]. CO₂ laser to induce dermal scarring may also be used to treat these lesions. Cellulitis and lymphangitis are also common complications for any patient with lymphatic malformations and these require prompt diagnosis and IV antibiotics [16].

Capillary malformations

Etiology/Epidemiology

Capillary malformations (CMs), more commonly called port wine stains, affect males and females equally and are usually visible at birth, occurring in 3/1000 newborns [14]. CMs may occur anywhere on the body and often follow a cutaneous sensory nerve distribution.

Natural history

As with most vascular malformations, CMs will grow proportionately with the patient over their lifetime, with some dilation of the capillary bed and darkening of the lesion as the patient gets older [14,16]. CMs are cutaneous lesions, but they may cause soft tissue and skeletal hypertrophy [16]. Although macular at birth, most CMs become slightly raised and nodular during adulthood, with varying degrees of fibrovascular ectasia [14,16] and intermittent breakdown and bleeding. When the lower extremities are involved, patients may develop hyperkeratosis or acanthosis of the overlying skin [8]. Aside from issues of cosmesis, these lesions rarely pose a significant threat to a person's health, but it must be stressed that they can signal an underlying structural abnormality [16].

Diagnosis

At birth, CMs may be confused with nevus flammeus neonatorum (stork bite), a lesion seen in 50% of newborns, which spontaneously disappears during the neonatal period.

The more important distinction to make is between the capillary malformation and the capillary hemangioma. These two entities may be clinically indistinguishable until the capillary hemangioma enters a phase of rapid proliferation and expansion during the first six months of life [14].

A CM may be the first indication of more significant developmental defects such as vertebral and spinal cord anomalies or the presence of ipsilateral ocular and leptomeningeal vascular malformations in association with a CM in the trigeminal nerve distribution (Sturge-Weber Syndrome) [16]. CMs may also be associated with venous, arteriovenous or lymphatic components. For this reason, clinical exam and imaging studies such as MRI should be used to determine whether the CM has an associated underlying abnormality that may significantly alter the patient's prognosis.

Treatment

In the absence of venous, arteriovenous, or lymphatic involvement, CMs are best treated with pulsed yellow-dye laser therapy under the care of a plastic surgeon or dermatologist. In rare instances of soft tissue or skeletal hypertrophy, surgical debulking may be appropriate. Nodular capillary ectasia and hyperkeratosis can be treated with local excision; however, recurrence is still a possibility [14].

Mixed-type malformations

Veno-lymphatic, capillary-veno-lymphatic, and the less common capillary-arterio-venous malformations all follow a clinical history similar to their single vessel counter parts, but in addition, they are associated with skeletal and/or soft tissue overgrowth.

Slow-flow malformations

Veno-lymphatic and capillary-veno-lymphatic malformations are both slow-flow anomalies that usually involve the lower extremities and may involve the trunk. Localized swelling or gross lymphedema of the entire extremity occurs, leading to skeletal and soft tissue hypertrophy and limb length discrepancies. Klippel-Trenaunay Syndrome is a common complication of mixed-type malformations and is defined as limb hypertrophy in the presence of a capillary-veno-lymphatic malformation (Fig. 3) [14,16,18]. The deep venous structures that drain the extremity are frequently anomalous, hypoplastic or absent, as are the lymphatic structures in 50% of patients with Klippel-Trenaunay Syndrome [16]. There may be associated persistence of fetal vessels that typically regress during embryological development. These altered deep venous structures and dilated superficial veins predispose to thrombophlebitis and pulmonary embolisms, observed in as many as 25% of patients [16]. The capillary component of these lesions usually becomes raised and nodular, and vesicles containing lymphatic fluid and blood are common. Although skeletal hypertrophy is more common, hypotrophy of the involved limb can also be seen [16].

Treatment

Treatment of slow-flow mixed-type malformations should emphasize compression garments to decrease the chronic lymphedema and venous engorgement since control of these symptoms may prevent or slow the skeletal hypertrophy seen in Klippel-Trenaunay syndrome [4,14,16,18]. Sclerotherapy, vein stripping, or debulking procedures can be done in selected instances, but evaluation with MRI or venographic studies is necessary beforehand to insure that anomalous superficial veins essential to extremity drainage are not removed [6]. Laser therapy is used for control of superficial vesicle formation. Sclerotherapy and staged debulking procedures are occasionally used for palliative treatment, however, complete excision of mixed malforma-

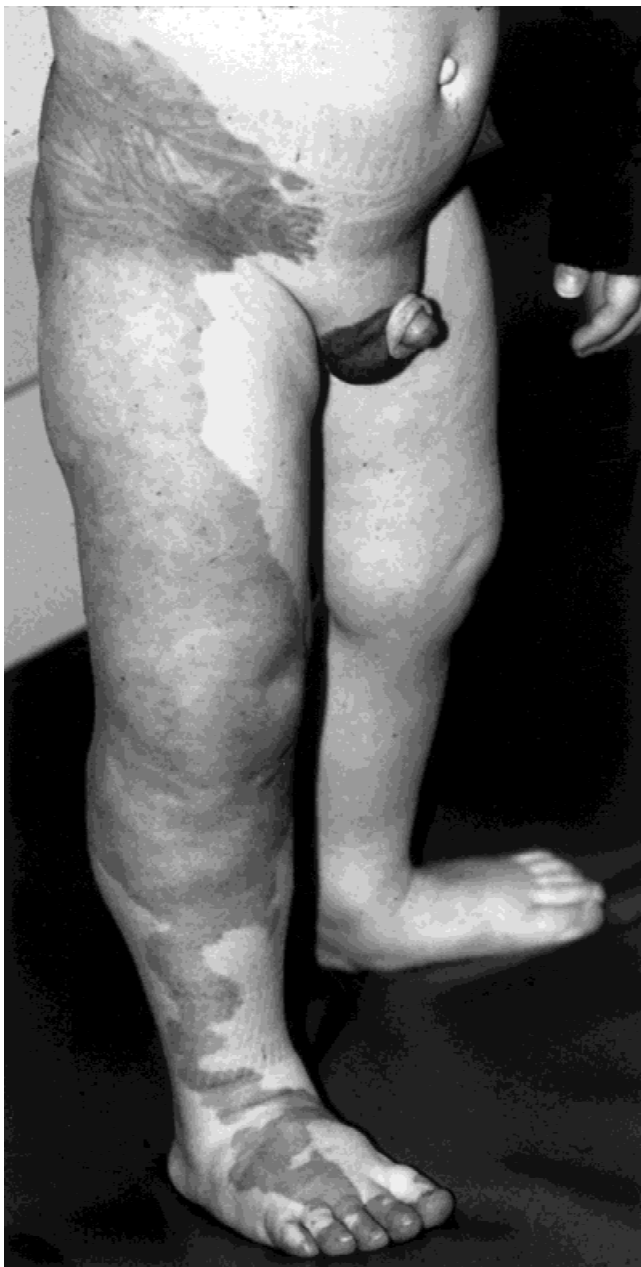

Fig. 3. Klippel-Trenaunay Syndrome involving the right lower extremity.

tions is rarely possible given their extensive anatomic involvement [14,16].

Fast-flow malformations

Capillary-arterio-venous malformations are essentially identical to the capillary-veno-lymphatic malformations of Klippel-Trenaunay Syndrome with the addition of AV fistulas (these are numerous, unlike traumatic AV fistulas). Fast-flow mixed-type malformations in association with limb length discrepancies are known as Parkes-Weber Syndrome. The presence of a bruit, thrill, or pulsation in the extremity often indicates the presence of AV fistulas. These lesions are also associated with increased likelihood of skeletal and muscular hypertrophy, as well. Prognosis for these patients is worse than for the Klippel-Trenaunay patients because the AV fistulas can lead to high-output cardiac failure [14]. In these cases, embolization of the AV fistulas is the most common intervention for control of the shunt.

Hemangiomas

Epidemiology

In contrast to vascular malformations, hemangiomas are true neoplastic lesions. The overwhelming majority of all hemangiomas are benign infantile hemangiomas, which have no potential for malignant transformation. Epithelioid hemangiomas, hemangiopericytomas, endovascular papillary angioendotheliomas, and angiosarcomas represent specific types of hemangioma with the potential for malignant transformation [4,9] (Table 1). Given the low incidence of these potentially malignant lesions in the general population, and their virtual non-existence in patients prior to the adolescent years [4], these will only be mentioned here. This discussion focuses on the infantile hemangioma, which represents the majority of all hemangiomas that will be encountered by the orthopaedic surgeon. After the early childhood years, however, any differential diagnosis of a vascular anomaly that does not present in a manner typical of an infantile hemangioma or vascular malformation should include these rare but potentially malignant hemangiomas.

Infantile hemangiomas are the most common benign soft tissue tumor of infancy, presenting in 4%–10% of all children and 30% of premature infants with a birth weight of 1,000 gm or less [14,18]. These lesions may be located in the superficial or deep dermis, subcutaneous tissue, musculature, bone, or viscera. As opposed to vascular malformations which affect males and females equally, hemangiomas occur more commonly in females, with a male:female ratio of 1:3 to 1:5, depending on the literature cited [14,16,18]. Sixty percent of all hemangiomas involve the head and neck, 25% involve the trunk, and 15% involve the extremities [14,18]. Twenty percent of patients with hemangiomas present with more than one lesion [16].

Etiology

Hemangiomas are benign, neoplastic endothelial cell tumors. They arise as newly formed vessels developing from

hyperplastic endothelial cells through the process of angiogenesis.

Natural history

Less than 50% of hemangiomas are visible at birth, but the majority present during the first month of life [14,16]. Although rare cases of facial hypertrophy have been documented with hemangiomas, hypertrophy of the trunk and extremities does not occur even in the case of extensive involvement. Usually the first indications of a hemangioma are a small red papule, telangiectasia, or an area of cutaneous blanching. Rarely, hemangiomas may be extensive and well formed at birth (congenital hemangioma), having undergone the initial proliferative phase in utero. The natural history of hemangiomas is pathognomonic and has three distinct phases referred to as proliferation, involution, and involuted (Table 4).

Diagnosis

Diagnoses of hemangiomas can be made by careful physical exam and observation of the natural history of the lesion 90% of the time (Table 2). Superficial hemangiomas will present as bright red lesions that can be macular (like a port wine stain) or raised and bossilated, while more deeply located hemangiomas appear purple or blue [18]. Dilated draining veins are often visible radiating from their center. Unlike vascular malformations, hemangiomas feel firm or rubbery to palpation during their proliferative stage, and compression will not cause complete extravasation of blood from the lesion [18]. Hemangiomas that are located deep to the deep fascia of the extremities and trunk may appear as only a soft tissue mass. Although hemangiomas may resemble a malformation, the distinct, disproportionate growth pattern indicates the diagnosis most of the time. When physical exam and natural history are not enough, ultrasound, CT, and MRI are all suitable imaging modalities for assessment of these lesions.

Histologically, a proliferating hemangioma demonstrates plump, rapidly dividing endothelial cells with hyperchromatic nuclei and abundant cytoplasm, but lacking atypical mitoses. The involution phase is characterized by dilation of the vascular lumen and flattened endothelial cells with decreased mitotic activity. By the time a lesion has reached the involuted phase, mature endothelial cells line the remaining capillary sized vessels which sit interspersed in a dense collagen and fibrofatty mass [16].

Complications

Common complications associated with hemangiomas include bleeding, ulceration, and intractable pain or severe cosmetic disfigurement. Intramuscular hemangiomas, those involving bone, or other structures deep to the deep fascial layer may cause pain, hematoma formation, or other complications, which can be best treated orthopaedic surgeon, however, limb length discrepancies and soft tissue hypertrophy do not occur. During the proliferative phase, obstruction of a vital structure such as the airway, GI tract, or the visual axis may pose a significant threat to the patient's well-being. Hemodynamic complications rarely occur, but are more common in deeper intramuscular, osseous, or visceral lesions and will require the surgical skills of an orthopedist to treat. These complications may include high output-cardiac failure or a platelet-trapping thrombocytopenia. When this thrombocytopenia is associated with a histologic subtype of hemangioma known as Kaposiform hemangioendothelioma or tufted hemangioma, it is referred to as Kasabach-Merritt Syndrome, which is associated with a 40% to 60% mortality rate [14,16].

Treatment

In the absence of intervention, partial or complete involution of hemangiomas usually occurs, and correction of cosmetic defects typically follows. When intervention for a rapidly expanding hemangioma is necessary, the first line of treatment is intralesional or systemic corticosteroids. For the 30% that fail steroid treatment, interferon α -2a treatment has shown to be effective as the next line of therapy, but has recently been associated with potentially reversible spastic diplegia in young patients, limiting its use to life-threatening cases [2,10]. Occasionally, when surgical resection is indicated for larger, deeper lesions that threaten normal function, staged excisions may be considered. However, in general, a team approach with a plastic surgeon is best for follow-up and treatment of patients with hemangiomas.

Associated Syndromes

Angiomatosis

Angiomatosis is a vascular syndrome that involves multiple tissue types (subcutis, muscle, or bone) or similar tissue types (multiple muscles) [19]. These lesions have also been called congenital arteriovenous fistula; diffuse, extensive, multifocal, or systemic angioma or hemangioma; infiltrating angiolipoma; or arteriovenous malformation [4].

Table 4. Hemangioma natural history

Stage	Clinical features
Proliferation	begins during weeks 1–4 of life rapid growth disproportionate to patient may cause local anatomy distortion/mass effect absence of osteolysis or skeletal/soft tissue overgrowth
Involution	begins 6–18 months of age color fades from bright red to dark purple/gray lesion more flaccid; wrinkled atrophic skin changes begin centrally and spread radially
Involuted	occurs by 7 years of age in 70% of patients and by 13 years of age in 90% 50% of patients retain cosmetic defects

Data from references [14], [18], and [4].

Differentiating between the variants of angiomas is difficult because of the spectrum of terminology and diagnostic parameters used. Generally, angiomas grow commensurately with the child and can be traced to an error in the development of the primitive vascular system [4]. The characteristics of angiomatosis are haphazard proliferation of small- or medium-sized blood vessels that diffusely infiltrate the skin, muscle, or bone. A large amount of adipose tissue usually accompanies the nests of capillaries and larger blood vessels. Treatment options include compression stockings, laser ablation, embolization, electrocautery, irradiation, local or systemic steroids, antiangiogenic therapies, and surgery. Because of the multivariate nature of the syndrome, angiomatosis may resemble or present with other syndromes and malformations.

Maffucci syndrome

A Maffucci lesion is a premalignant condition in which there coexist exophytic vascular anomalies with bony exostoses and enchondromas. This disorder is largely undetectable at birth and is thought to be sporadic. The osseous lesions appear in childhood, whereas the vascular lesions appear later. The syndrome often occurs in the subcutaneous tissue and bone of the limbs, occurring both unilaterally and bilaterally. Maffucci lesions can also appear as lymphaticovenous malformations of the fingers and toes or as vascular proliferations within pre-existing vascular malformations [14]. Patients typically develop hemangioendothelioma. The occurrence of 20%–30% malignant transformation suggests the involvement of a tumor suppressor gene [16].

Future Directions of Diagnosis and Treatment

The past decade has seen many advances in the diagnosis and treatment of vascular anomalies, ranging from the establishment of a comprehensive nomenclature system to the discovery of genetic markers associated with the processes of angiogenesis and vasculogenesis [3,22].

Most importantly, the future of improved diagnosis and treatment of vascular malformations and hemangiomas depends upon the combination and cooperation of multiple specialties. The collaboration of orthopedic surgeons with plastic and general surgeons, hematologists, dermatologists, and interventional radiologists will provide the most expedient diagnosis and comprehensive care for patients with vascular anomalies.

Although the imaging techniques of today are adequate to visualize the nature, extent, and flow of vascular anomalies, new immunohistochemical assays, albeit less comprehensive, may provide additional diagnostic alternatives [21]. Further research into the genetic characteristics of vascular anomalies may aid in the diagnosis of various vascular anomalies, allowing earlier intervention and eliminating the need for an observation period to differentiate a hemangioma from a vascular malformation.

Treatment of hemangiomas should continue to advance with the introduction of new antiangiogenic agents, such as

interferon α -2a [10,11], and improved methods of drug-delivery to designated vascular sites [1,12,20].

Summary

Vascular malformations and hemangiomas are commonly encountered lesions in the pediatric population that may involve the musculoskeletal system. Orthopaedic surgeons must be familiar with the clinical and radiographic characteristics of vascular anomalies because they may appear similar to other potentially malignant musculoskeletal tumors on initial presentation. Use of the biological classification system aids in this differentiation and allows an easier understanding of the diagnosis and prognosis for the patient. The overwhelming majority of all hemangiomas are benign infantile hemangiomas that will eventually regress. Conversely, with vascular malformations regression of this lesion will not occur, and intramuscular, articular, and bone involvement may require intervention by an orthopaedic surgeon. A team approach to the treatment of vascular anomalies involving orthopaedic, plastic, dermatological, interventional radiological, and pathologic specialties represents the most effective method of diagnosis and treatment for these patients.

References

1. Arap W, Pasqualini R, Ruoslahti E. Cancer treatment by targeted drug delivery to tumor vasculature in a mouse model. *Science* 279:377–380, 1998.
2. Boon LM, Brouillard P, Irrthum A, Karttunen L, Warman ML, Rudolph R, Mulliken JB, Olsen BR, Viskula M. A gene for inherited cutaneous venous anomalies localizes to chromosome 1p21–22. *Am J Hum Genet* ;65:125–133, 1999.
3. Coffin CM: Vascular tumors. In: Coffin CM, O'Shea PA, editors. *Pediatric soft tissue tumors: a clinical, pathological, and therapeutic approach*. Baltimore: Williams and Wilkins; p 40–79, 1997.
4. Cohen JM, Weinreb JC, Redman HC. Arteriovenous malformations of the extremities: MR imaging. *Radiology* 158:475–479, 1986.
5. Damron TA, Rock MG: Diagnostic strategies and biopsy. In: Simon MA, editor. *Surgery for bone and soft tissue tumors*. Philadelphia: Lippincott-Raven Publishers; p 509–523, 1998.
6. Dubois J, Garel L. Imaging and therapeutic approach of hemangiomas and vascular malformations in the pediatric age group. *Pediatr Radiol* 29:879–893, 1999.
7. Enzinger FM, Weiss SW: Benign tumors and tumorlike lesions of blood vessels. In: Enzinger FM, editor. *Soft Tissue Tumors*. St. Louis, MO: The C.V. Mosby Company; p 489–532, 1988..
8. Enzinger FM, Weiss SW: Hemangioendothelioma: vascular tumors of intermediate malignancy. In: Enzinger FM, editor. *Soft tissue tumors*. St. Louis, MO: The C.V. Mosby Company; p 533–544, 1988.
9. Ezekowitz RA, Mulliken JB, Folkman J. Interferon alfa-2a therapy for life-threatening hemangiomas of infancy. *N Engl J Med* 326:1456–1463, 1992.
10. Kaban LB, Mulliken JB, Ezekowitz RA, Ebb D, Smith PS, Folkman J. Antiangiogenic therapy of a recurrent giant cell tumor of the mandible with interferon alfa-2a. *Pediatrics* 103:1145–1149, 1999.
11. Keshet E, Ben-Sasson SA. Anticancer drug targets: approaching angiogenesis. *J Clin Invest* 104:1497–1501, 1999.
12. Kohout MP, Hansen M, Pribaz JJ, Mulliken JB. Arteriovenous malformations of the head and neck: natural history and management. *Plast Reconstr Surg* 102:643–654, 1998.

13. Low DW. Hemangiomas and vascular malformations. *Semin Pediatr Surg* 3:40–61, 1994.
14. Meyer JS, Hoffer FA, Barnes PD, Mulliken JB. Biological classification of soft-tissue vascular anomalies: MR correlation. *AJR Am J Roentgenol* 157:559–564, 1991.
15. Mulliken JB, Fishman SJ, Burrows PE. Vascular anomalies. *Curr Probl Surg* 37:517–584, 2000.
16. Mulliken JB, Glowacki J. Hemangiomas and vascular malformations in infants and children: a classification based on endothelial characteristics. *Plast Reconstr Surg* 69:412–422, 1982.
17. Mulliken JB, Young AE. *Vascular birthmarks, hemangiomas, and malformations*. Philadelphia: WB Saunders Company; 1988.
18. Rao VK, Weiss SW. Angiomatosis of soft tissue. An analysis of the histologic features and clinical outcome in 51 cases. *Am J Surg Pathol* 16:764–771, 1992.
19. Springer ML, Chen AS, Kraft PE, Bednarski M, Blau HM. VEGF gene delivery to muscle: potential role for vasculogenesis in adults. *Mol Cell* 2:549–558, 1998.
20. Takahashi K, Mulliken JB, Kozakewich HP, Rogers RA, Folkman J, Ezekowitz RA. Cellular markers that distinguish the phases of hemangioma during infancy and childhood. *J Clin Invest* 93:2357–2364, 1994.
21. Towbin JA, Casey B, Belmont J. The molecular basis of vascular disorders. *Am J Hum Genet* 64:678–684, 1999.